


**PATIENT**

Louie Rule

**PRESENTING CLINICAL SIGNS**

History: Grade 2/6 heart murmur. Abnormal ProBNP: 130. Sedated with Torb.

**SPECIES**

Feline

**BREED**

Ragamuffin

**SEX**

Male Neutered

**AGE**

4 years

**WEIGHT**

18.1lbs

**INTERPRETED BY**

 Maggie Machen Lamy,  
 DVM, DACVIM  
 (Cardiology)

**IMAGING PERFORMED BY**

A. Nicastro, DVM

**HOSPITAL NAME**

 Salt Marsh Animal  
 Hospital

**REFERRING VET**

Dr. Wiles

**INVOICE**

28977

**DATE**

2/14/23

**ECHOCARDIOGRAM FINDINGS**

2D, m-mode, color flow and doppler imaging is available. The left ventricular wall is mildly increased in dimension. There is a diffusely hyperechoic endocardium consistent with fibrosis. Mild symmetric papillary muscle hypertrophy and remodeling. The right ventricle is subjectively normal in size and morphology. There is mild left atrial enlargement present. No right atrial enlargement present. Normal RVOT velocity. No TR. Normal LVOT velocity. The mitral valve is mildly thickened with no significant MR. Trace Pi. There is no pericardial effusion noted. No pleural effusion appreciated. No obvious cardiac tumors.

**CARDIAC CHART**

FELINE CARDIAC PARAMETERS	BODY WEIGHT (kg)	HR (BPM)	IVSd (cm) (Moise, Pipers)	LVIDd (cm) (Moise, Pipers)	LWVd (cm) (Moise, Pipers)	FS (%)	EF (%)
NORMAL PARAMETER	-----	150-240	0.35-0.55	<2 (mean 1.5)	3.5-0.55	35-67	80-100
PATIENT	8.2	NM	0.65	1.47	0.62	58	90
FELINE CARDIAC PARAMETERS	LA/AO (Boon)	LA/AO HEART BASE (Swe) (Abbott)	LA 2D short axis Base view (cm) (Abbott)		LVOT VEL (m/s)	RVOT VEL (m/s)	E max (m/s)
NORMAL	<1.5	<1.3	<1.2		<1.6	<1.3	<0.9
PATIENT	NM	1.5	1.4		1.1	0.7	NM

*\*Note: All measurements based upon multi-modal images and methods. An average value is reported.*  
 Adapted from June Boon, Veterinary Echocardiography, 1998  
 Abbott J & MacLean H JVIM 2006;20: 111-119, Moise et al. Am J Vet Res 47:1476, 1986. Pipers et al. Am J Vet Res 40:882, 1979.

**INTERPRETATION OF THE FINDINGS & FURTHER RECOMMENDATIONS**

Hypertrophic cardiomyopathy (HCM) is a rule out diagnosis once a patient is deemed normotensive and euthyroid. Both should be ruled out in this case as contributing factors; however, in a 4 yo cat primary changes are suspected. It is worth noting that this is a very large cat, and measurements may simply be normally increased for this body size (as is seen in some Maine Coons). Regardless, what is seen here is mild, with only mild LVH and mild LA dilation. This would indicate the risk for clinical issues is low at this time. Follow up is recommended to screen for progression. No additional issues are identified. No cause for the murmur is identified in this study, making it likely physiologic in origin.

No medications are indicated prior to significant atrial dilation. It is important to note that no medications have been shown to definitively alter long term outcome at this stage, particularly in the absence of SAM.

Monitor at home for any respiratory issues or signs of blood clot events (neurologic change, paralysis, etc.). Anesthetic risk is considered mild, however judicious fluid administration is advised if needed with careful RR/RE monitoring to screen for fluid overload. Additionally, drugs that stimulate heart rate should be avoided unless clinically necessary (glycopyrrolate, atropine).



**PATIENT**

Louie Rule

Risk for complication with steroid use typically follows LA dilation, which in this case is mildly elevated. If needed, monitoring of RR/RE is advised particularly in the initiation phase.

**SPECIES**

Feline

**PLAN**

A screening blood pressure and T4 are recommended every 6-12 months lifelong.

**BREED**

Ragamuffin

A recheck echocardiogram is recommended in 6 months to assess for progression, sooner if any issues arise in the interim.

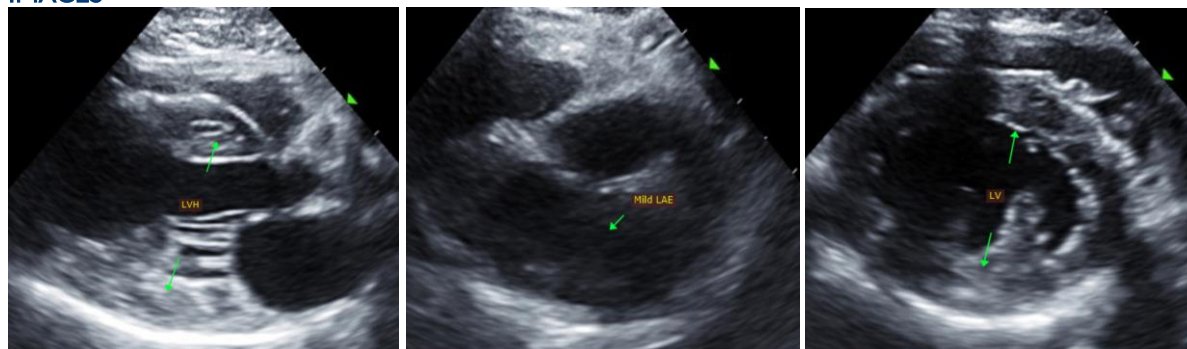
**SEX**

Male Neutered

**IMAGES**

**AGE**

4 years



**WEIGHT**

18.1lbs

The information and recommendations provided are based on the images presented by the referring veterinarian. No evaluation can be communicated regarding pathology that was not visible in the image/video clips provided.

**INTERPRETED BY**

Maggie Machen Lamy,  
DVM, DACVIM  
(Cardiology)

Thank you for this referral. This report was generated using transcription software, and minor dictation errors may be present. If the clinical or image interpretation does not parallel your findings or if I can be of any further assistance, please contact me.

**IMAGING PERFORMED BY**

A. Nicastro, DVM

Maggie Machen Lamy, DVM  
Diplomate of the American College of Veterinary Internal Medicine (Cardiology)  
info@sonopath.com

**HOSPITAL NAME**

Salt Marsh Animal  
Hospital

**REFERRING VET**

Dr. Wiles

**INVOICE**

28977

**DATE**

2/14/23